



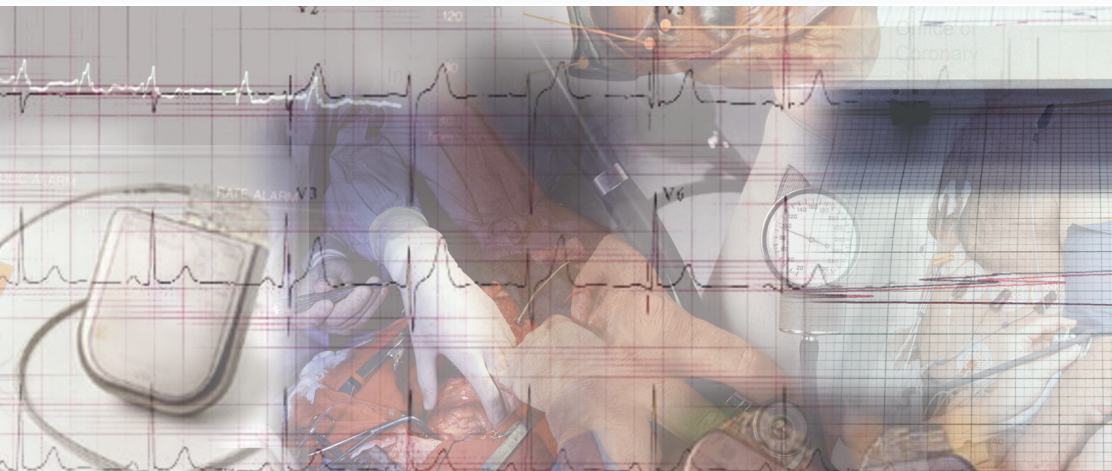Arrhythmia Alliance

The Heart Rhythm Charity

Promoting better understanding, diagnosis, treatment and quality of life for individuals with cardiac arrhythmias

Registered Charity No. 1107496 ©2006

Tachycardia (Fast Heart Rhythm)



Introduction

This booklet is intended for use by people who wish to understand more about Tachycardia. The information within this booklet comes from research and previous patients' experiences. The booklet offers an explanation of Tachycardia and how it is treated, alongside true life success stories. Additional information can be sourced at the provided websites.

This booklet should be used in addition to the information given to you by doctors, nurses and physiologists. If you have any questions about any of the information given in this booklet, please ask your nurse, doctor or cardiac physiologist.

Contents

The normal electrical system of the heart

Diagram of the heart's electrical system

What are Arrhythmias?

What happens in the heart to cause an arrhythmia?

What can trigger an arrhythmia?

How do I know what kind of arrhythmia I have?

Electrocardiogram (ECG)

Holter monitor

Cardiac event monitor

Types of Arrhythmia

Supraventricular Tachycardia (SVT)

AV Nodal Reentry Tachycardia (AVNRT)

AV Reentry Tachycardia (AVRT) or Wolff-Parkinson White Syndrome (WPW)

Atrial Fibrillation

Atrial Flutter

Ventricular Tachycardia (VT)

Ventricular fibrillation

What treatments are available to me?

Medicines

Permanent Pacemaker

Radiofrequency Catheter Ablation

Internal Cardioversion

Implantable Cardioverter-Defibrillator

Further Information

*Arrhythmia Alliance patient booklets are reviewed annually.
This booklet will be next updated December 2007 if you have any
comments or suggestions please contact [A-A](#).*

Glossary of technical terms used

Atrium	Top chambers of the heart that receive blood from the body and from the lungs. The right atrium is where the heart's natural pacemaker (sino atrial node) can be found.
Arrhythmia	An abnormal heart rhythm.
Bradycardia	A slow heart rate, normally less than 60 beats per minute.
Cardiac Arrest	When the heart stops beating.
Cardioversion	The use of a small energy shock to stop fast heart rhythms.
Defibrillation	The use of a higher energy shock to stop fast heart rhythms.
Heart attack	Occurs when one of the coronary arteries becomes blocked by a blood clot. The blood supply to part of the heart muscle is blocked, causing part of the heart muscle to die.
Tachycardia	Fast heart rhythm.
Ventricles	The two lower chambers of the heart. The right ventricle pumps blood into the lungs and the left ventricle pumps blood around the body.
Ventricular Fibrillation (VF)	A fast, dangerous heart rhythm which causes the heart to stop pumping. This rhythm needs a shock to stop it and return the heart back to a normal rhythm. A cardiac arrest can soon follow if the rhythm is not treated quickly with a shock.
Ventricular Tachycardia	A fast rhythm which causes the heart to pump less efficiently, and can lead to dizziness, fainting and unconsciousness. If not treated with medication or an electric shock, the rhythm can lead to ventricular fibrillation.

The normal electrical system of the heart

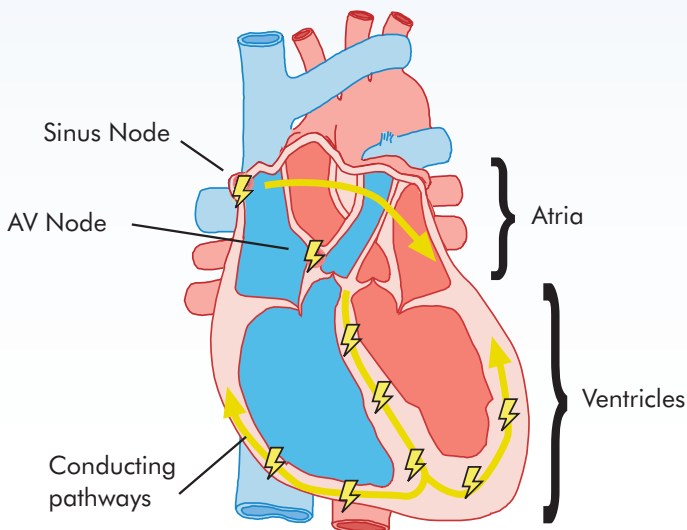
The heart has its own electrical conduction system. The conduction system sends signals throughout the upper (atria) and lower (ventricles) chambers of the heart to make it beat in a regular, coordinated rhythm. The conduction system consists of two areas called nodes that contain conduction cells and special pathways that transmit the impulse.

The normal heartbeat begins when an electrical impulse is fired from the sinus node (SA node), in the right atrium. The sinus node is responsible for setting the rate and rhythm of the heart and is therefore referred to as the heart's "pacemaker".

The electrical impulse fired from the SA node spreads throughout the atria, causing them to contract and squeeze blood into the ventricles. The electrical impulse then reaches the atrioventricular node (AV node), which acts as a gateway, slowing and regulating the impulses travelling between the atria and the ventricles. As the impulse travels down the pathways into the ventricles the heart contracts and pumps blood around the body. The cycle then begins all over again.

The normal adult heart beats in a regular pattern 60-100 times a minute; this is called sinus rhythm.

Diagram of the heart's electrical system



What are Arrhythmias?

Arrhythmias are disorders of your heart's electrical system whereby there is a change in the regular beat of your heart. Sometimes if the conduction pathway is damaged or becomes blocked, or if an extra pathway exists, the heart's rhythm changes. The heart may beat too quickly (tachycardia), too slowly (bradycardia) or irregularly which may affect the heart's ability to pump blood around the body. These abnormal heartbeats are known as arrhythmias. Arrhythmias can occur in the upper chambers of the heart, (the atria) or in the lower chambers of the heart, (the ventricles). Arrhythmias may occur at any age, and are most often a nuisance rather than a serious problem.

What happens in the heart to cause an arrhythmia?

Any interruption in the heart's electrical system can cause an arrhythmia. For example, an irregular heartbeat may begin with an abnormal impulse in a part of the heart other than the normal pacemaker (the sinus node). Or the sinus node may develop an abnormal rate or rhythm.

What can trigger an arrhythmia?

Common causes of arrhythmias include stress, caffeine, tobacco, alcohol, diet pills, and cough and cold medicines. If your heart tissue is damaged as a result of acquired heart disease such as myocardial infarction (heart attack) or congenital heart disease you may also be at risk of developing arrhythmias. For some patients, however, doctors cannot identify a cause of their arrhythmias.

How do I know what kind of arrhythmia I have?

If your doctor suspects that you may have an arrhythmia, one or more of the following tests may be performed to determine the cause of your symptoms.

Electrocardiogram (ECG)

An electrocardiogram is a recording of the electrical activity of your heart. Electrode stickers are placed on your chest and connected by wires to a recording machine. Your heart's electrical signals produce a pattern on graph paper in the ECG. By analysing the pattern of these waves, your doctor can often determine what type of arrhythmia you have. ECG testing can be done at rest, or while you are exercising on a treadmill.

Holter monitor

A Holter monitor shows changes in your heart rhythm over the course of a 24-hour period that may not be detected during a resting or exercise ECG. If your doctor wants you to have this test, you will be asked to go about your daily activities as usual (except for showering or bathing) while you wear a small, portable recorder that connects to electrode stickers on your chest. You will be asked to come back to the hospital the next day so that the information can be retrieved and analysed.

Cardiac event monitor

If your doctor feels you need to be monitored for several days or weeks, you may need to have a cardiac event monitor. Your doctor may use this type of recording device if your arrhythmias are infrequent. This device is about the size of a large pager, and can be clipped to your belt or waistband or carried in your purse or pocket. When you feel symptoms, you simply hold the recorder against your chest and press a button; the device then records up to 70 seconds of ECG readings.

Types of Arrhythmia

Arrhythmias that occur in the atria (the top chambers of the heart) are either atrial or supraventricular (above the ventricles) in origin whereas ventricular arrhythmias start in the ventricles (the lower chambers of the heart). While some arrhythmias are merely a nuisance, others can be life-threatening. A doctor will determine which type of arrhythmia you may have and treat your symptoms accordingly. In general, ventricular arrhythmias caused by heart disease are the most serious kind, and require prompt medical attention.

Supraventricular Tachycardia (SVT)

This type of arrhythmia commonly occurs in young, healthy people. Doctors often refer to supraventricular tachycardia (SVT) as re-entry tachycardias as the electrical impulse does not fade out as with the normal heartbeat but continues to move in a rapid circle within the conduction system. This is due to an extra electrical pathway which can form a short circuit within the heart's conduction system. SVT is usually a rapid, regular rhythm. The two most common types of SVT are AV-node re-entry tachycardia (AVNRT).

AV Nodal Re-entry Tachycardia (AVNRT)

This type of arrhythmia occurs when a problem arises in the way the electrical impulses pass through the AV node. Normally, the AV node acts as a gateway slowing and regulating the impulses as they travel between the atria and the ventricles. In AV Nodal re-entry Tachycardia (AVNRT) there are two pathways, known as dual conduction pathways, that can pass impulses to and from the AV node. This type of arrhythmia usually starts following an early beat (ectopic). An electrical short circuit then occurs whereby the electrical impulse rotates around the circuit and with each cycle passes to the ventricles resulting in a very fast heartbeat.

AV Re-entry Tachycardia (AVRT) and/or Wolff-Parkinson White Syndrome (WPW)

In AVRT an extra electrical pathway exists that bypasses the normal conduction system. The pathway directly connects the atria (top chambers of the heart) to the ventricles (the bottom chambers of the heart). This extra pathway is known as an accessory pathway. This can be a concealed pathway, meaning there is no evidence of the extra pathway on your ECG, or in WPW. The electrical impulses travel along the accessory pathway thereby bypassing the atrioventricular node. The tissue in the pathway does not slow the impulse down, as in the AV node. Therefore the electrical impulses reach the ventricles before the 'normal' electrical impulse (this is known as pre-excitation). An ECG recording of a patient with WPW syndrome will often show a delta wave which shows the existence of an extra electrical pathway. Very fast heart rates may occur as the electrical impulse bounces between the atria and ventricles.

Atrial Fibrillation

Atrial fibrillation (AF) is one of the most common types of arrhythmia. Atrial fibrillation occurs in the atria, in the upper chambers of the heart. The electrical impulse normally originates at the SA node. However in atrial fibrillation, many electrical impulses are fired rapidly and at random throughout the atria down to the ventricles. The resulting heartbeat is irregular and usually fast. Because the atria are beating rapidly and irregularly (fibrillating), they are unable to completely empty all the blood they receive into the ventricles and this can cause blood clots to form. Therefore, if you are at an increased risk of stroke you may be treated with an anticoagulant (blood thinner) called warfarin.

Atrial Flutter

Atrial flutter also occurs in the atria (the upper chambers of the heart). In atrial flutter the electrical impulses fire rapidly but the resulting rhythm is regular and organised. The rhythm is due to a re-entry circuit within the atria, whereby the electrical impulse travels in circles leaving and arriving back at the same point.

Ventricular Tachycardia (VT)

Ventricular tachycardia (VT) occurs when the electrical impulses arise in the ventricles, the bottom chambers of the heart. The ventricles start beating at an abnormally fast, regular rate. Because the ventricles are beating rapidly the heart does not work as efficiently. This can cause symptoms of weakness, dizziness, chest pain, shortness of breath or even collapse. There are several different types of ventricular tachycardia (VT) and the seriousness of the condition can vary. However, ventricular tachycardia (VT) can be a potentially life threatening heart rhythm as it can progress to ventricular fibrillation and cause the heart to stop beating (cardiac arrest).

There are a number of reasons why people may develop ventricular tachycardia (VT). For example, in people who have had a previous myocardial infarction (heart attack), the area of the heart muscle damaged by the heart attack forms scar tissue and this can make the heart susceptible to abnormal heart rhythms. Other people who may experience ventricular tachycardia (VT) are patients with cardiomyopathy, previous corrective congenital heart surgery or inherited arrhythmias. There is also a small group of people who have VT with a structurally normal heart.

Ventricular fibrillation

Ventricular fibrillation occurs in the ventricles, in the bottom chambers of the heart. In Ventricular fibrillation, the electrical impulses are fired from multiple sites in the ventricles in a very fast and irregular way, causing the heart to quiver rather than to beat and pump blood. Ventricular fibrillation is an extremely dangerous heart rhythm and prompt emergency care must be provided to get the heart pumping again, or death can occur.

What treatments are available to me?

The results of the tests you have had will determine the type and seriousness of your arrhythmia and your doctor will then discuss with you the treatment options available. You and your doctor will then decide which one is right for you. Remember, many patients with arrhythmias require no further treatment. The most important aspect of any initial evaluation is to determine the significance of the arrhythmia and the need for any type of intervention.

Medicines

There are a number of drugs that can be used to treat your arrhythmia. Anti-arrhythmic drugs are medicines that change the electrical signals in your heart and help prevent irregular or rapid heart rhythms.

Permanent Pacemaker

If you have a slow heart rate your doctor may recommend you have a pacemaker. A pacemaker is a small device used to treat slow heart rhythms, it is implanted beneath the skin below the collarbone and connected to a pacing wire placed inside the heart. The pacemaker delivers a small electrical impulse to stimulate the heart to beat when it is going too slowly.

Radiofrequency Catheter Ablation

If you have an extra electrical pathway or group of cells your doctor may advise you to have a radiofrequency catheter ablation. A radiofrequency catheter ablation blocks the area of extra electrical activity causing the arrhythmias, providing relief for those of you who may not have responded well to medications or, for whatever reason, would rather not or cannot take medications. This technique has a high percentage of successfully "curing" many types of arrhythmias.

Internal Cardioversion

Internal cardioversion is a low energy electrical shock delivered inside the heart. Two catheters are inserted into a vein in your groin and a small electrode pad applied to your chest. Your Electrophysiologist performs this procedure in the EP lab. During the internal cardioversion, you will be given a short acting sedative to make you sleepy. Internal cardioversion is performed when medications and external cardioversion have been unsuccessful in returning a patient's rhythm back to a normal sinus rhythm.

Implantable Cardioverter Defibrillator

This is a device for people who are at risk of life threatening heart rhythms. It is slightly larger than a pacemaker and usually implanted beneath the skin below the collarbone. It is connected to defibrillation/pacing wire(s) positioned inside the heart via a vein. It has the ability to determine and stop fast ventricular arrhythmias by using extra paced beats, or delivering an electric shock to the heart. It is also capable of pacing the heart to stop it from going too slowly.

Useful Websites

A list of useful sites can be found at :-

www.arrythmiaalliance.org.uk - This list is not exhaustive and it is constantly evolving. If we have excluded anyone, please accept our sincerest apologies, and be assured that as soon as the matter is brought to the attention of the **Arrhythmia Alliance**, we will quickly act to ensure maximum inclusiveness in our endeavours.

Finally

Please feel free to discuss any concerns you may have with your doctor, physiologist or your specialist nurse at any time.



Executive Committee

President - Prof A John Camm

Dr Phillip Batin	Mr Steve Gray	Dr John Morgan
Mr Pierre Chauvineau	Mr Robert Hall	Mrs Jayne Mudd
Dr Derek Connelly	Dr Guy Haywood	Dr Francis Murgatroyd
Dr Campbell Cowan	Mrs Anne Jolly	Dr Richard Schilling
Ms Fiona Cooke	Mrs Sue Jones	Dr Graham Stuart
Dr Neil Davidson	Dr Gerry Kaye	Mrs Jenny Tagney
Dr Wyn Davies	Mrs Trudie Lobban	Mr Paul Turner
Dr Adam Fitzpatrick	Ms Nicola Meldrum	

Trustees - Dr Derek Connelly Dr Adam Fitzpatrick Mrs Trudie Lobban

Patrons - Prof Hein J J Wellens Prof Silvia G Priori W B Beaumont, OBE

Please remember these are general guidelines and individuals should always discuss their condition with their own doctor.



PO Box 3697 Stratford upon Avon
Warwickshire CV37 8YL
Tel: 01789 450787
e-mail: info@arrhythmiaalliance.org.uk
www.arrhythmiaalliance.org.uk